

GE Healthcare

# GE quantitative analysis for left ventricular function

Vivid 7 Dimension



# GE quantitative analysis overview

Echocardiography traditionally has been all about the image – a fast moving image. From this image, the experienced eye may be able to identify irregularities in myocardial motion and left ventricular (LV) function. This, coupled with its non-invasive nature, has made echocardiography one of the leading diagnostic imaging techniques.

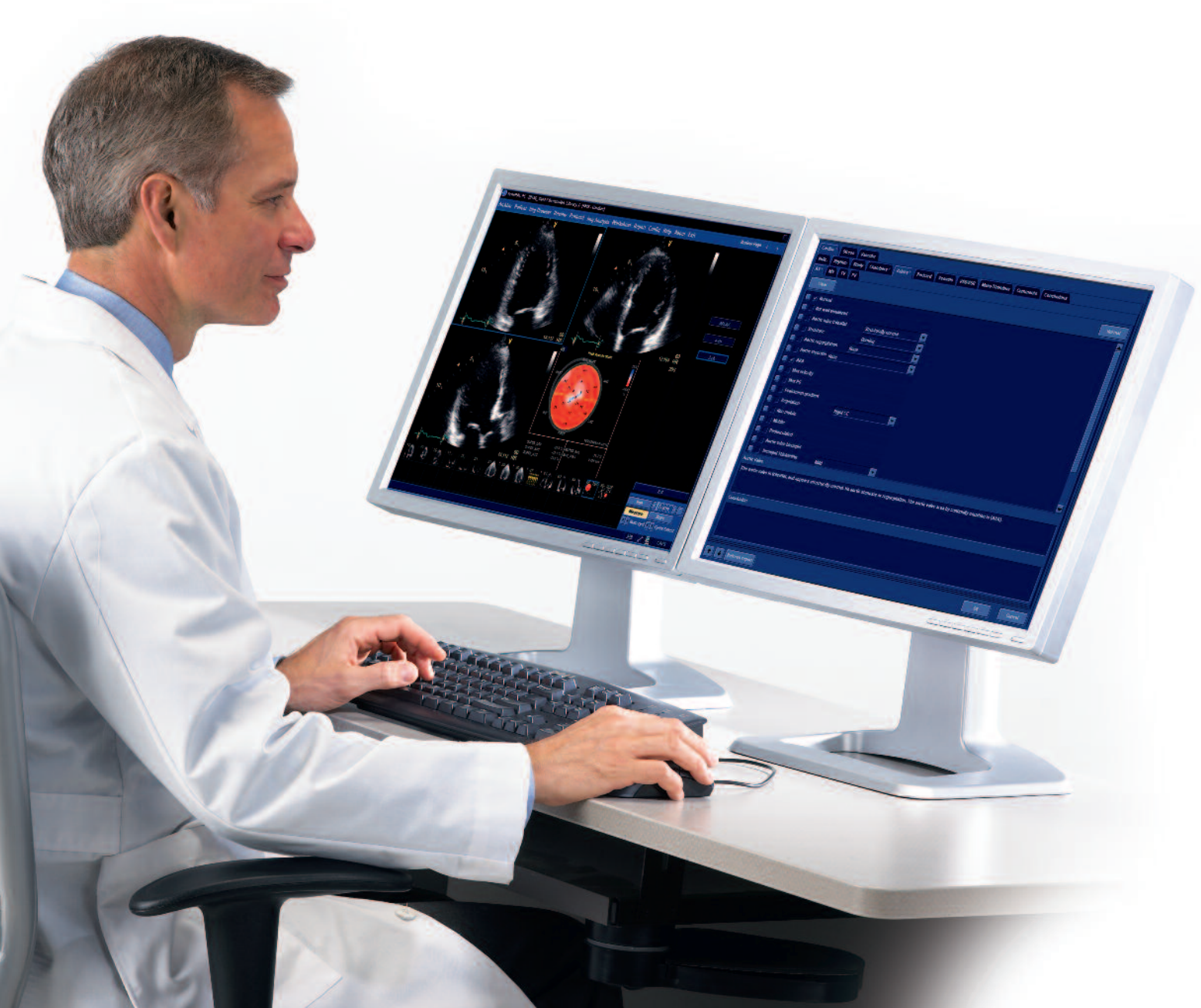Current ultrasound scanner technology generates images of several hundred frames per second, which is beyond the perception of even the most experienced eye. This created the need for an enhanced quantitative assessment tool for LV function, called QScan.

The first QScan tool, Anatomical M-Mode, was introduced in the early 1990s to derive quantitative information from high-frame-rate, raw-data images.

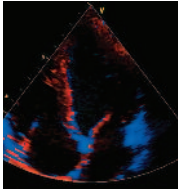
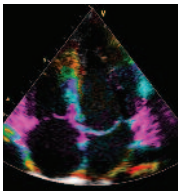
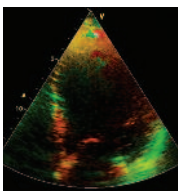
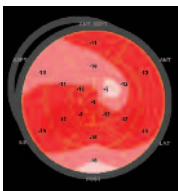
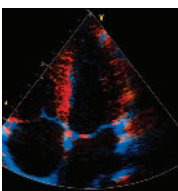
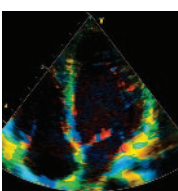
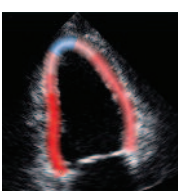
In 1995, QScan technology was applied to Tissue Velocity Imaging (TVI). TVI derives velocity traces and anatomical and curved Anatomical M-Mode information, which initiated new clinical applications.

Building on QScan technology, GE introduced Tissue Tracking to help assess longitudinal displacement. Strain and Strain Rate Imaging was also introduced with clinical applications to help with regional assessment of LV function. The Vivid\* 7 Vantage release introduced another new quantitative QScan tool (TSI) developed to support cardiac resynchronization therapy (CRT).

In 2004, on the Vivid 7 Dimension release, GE introduced 2D Strain, a unique, advanced research tool that leverages its innovation in quantitative echocardiography and includes its latest breakthroughs in Strain and Strain Rate Imaging.



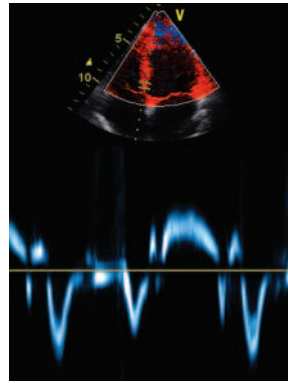
## GE quantitative assessment tools for LV function

Mode	Parametric image	Measurement	Clinical application
<b>TVI</b> Tissue Velocity Imaging	 <p>Speed</p>	Measures longitudinal myocardial velocities (cm/sec)	Helps assess global and regional systolic function; assess left ventricular relaxation abnormalities
<b>TT</b> Tissue Tracking	 <p>Distance</p>	Integrates TVI over time to yield longitudinal wall displacement (mm)	Easy recognition of regional and global left ventricular wall motion abnormalities
<b>TSI</b> Tissue Synchronization Imaging	 <p>Synchrony</p>	Color-coded, time-to-peak velocity (ms)	Unique tool to help assess asynchrony in the left heart, manage heart failure patients and those patients undergoing CRT
<b>AFI</b> Automated Function Imaging	 <p>Deformation</p>	Regional and global peak longitudinal strain (%)	Helps assess left ventricular function at rest
<b>S</b> Strain	 <p>Deformation</p>	Measures regional longitudinal deformation (%)	Helps evaluate ischemic heart disease; true analysis of a specific piece of the myocardium
<b>SRI</b> Strain Rate Imaging	 <p>Speed of deformation</p>	Measures regional myocardial compression speed (deformation rate)	Helps evaluate ischemic heart disease; true analysis of a specific piece of the myocardium
<b>2DS</b> 2D Strain	 <p>Deformation</p>	Advanced research tool based on 2D speckle tracking	Helps in the evaluation of longitudinal, radial and circumferential myocardial deformation/strain

## Tissue Velocity Imaging

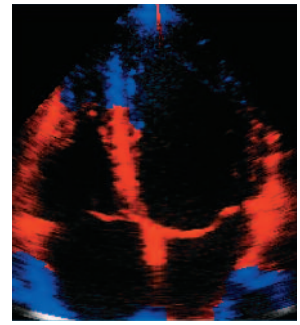
Tissue Velocity Imaging (TVI) uses myocardial Doppler frequency shifts to quantify myocardial tissue motion. TVI can be used to help assess global and regional systolic function, as well as left ventricle relaxation abnormalities. TVI is based on the Doppler-shifted part of the reflected signal. This gives the clinician a tool to help assess myocardial function, even though the two-dimensional image quality may be sub-optimal. Just as with conventional Doppler, TVI can be displayed as pulsed Doppler (Figure 1), color Doppler (Figure 2) and color M-Mode (Figure 3).

GE allows access to raw data, which gives you the ability to quantify TVI live or at a future time by simply storing a 2D color TVI image. You can then go into Q-Analysis and acquire TVI waveforms (Figure 4). You can also convert the TVI information from the raw data to display Tissue Tracking, Tissue Synchronization Imaging, Strain or Strain Rate Imaging.




**Figure 1. Pulse Wave TVI**

Normal spectral wave displays a positive wave in systole and a negative wave in diastole, representing early filling and atrial filling.



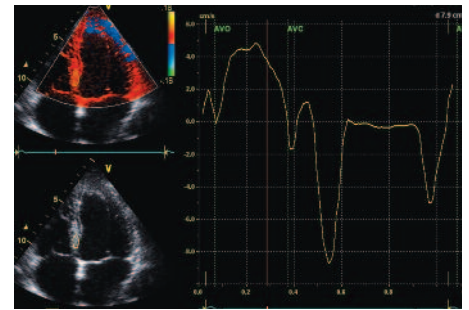
**Figure 2. Color TVI**

Red color displays motion toward the probe. Blue color displays motion away from probe.



**Figure 3. TVI M-Mode**

Red color in systole displays tissue motion toward the probe, while blue in diastole displays motion away.



**Figure 4. TVI Waveforms**

Waveforms may be extracted at any time from color TVI loops in the quantitative analysis mode on Vivid 7 or EchoPAC.

## Tissue Tracking

Tissue Tracking displays systolic longitudinal displacement by integrating tissue velocity over time. Tissue Tracking is displayed as a color band representing motion during systole. The system color codes each point in the myocardium with the displacement occurring from end diastole to end systole (see Figure 5).

Tissue Tracking is performed from the apical views. A normal left ventricle will display the lowest motion at the apex, while the mitral annulus will display the greatest motion. Systolic mitral annular displacement, determined by tissue tracking, correlates closely with left ventricular ejection fraction.<sup>2</sup>



**Figure 5. Tissue Tracking**

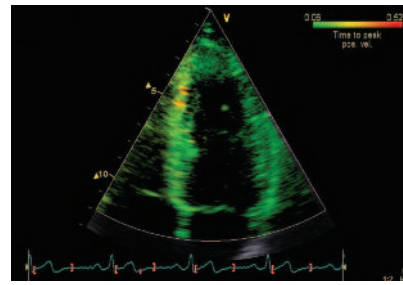
Tissue Tracking represents myocardial motion or distance during systole. The motion is displayed as a color band representing distance in mm.

## Tissue Synchronization Imaging

Tissue Synchronization Imaging (TSI) is a parametric imaging tool based on Tissue Velocity Imaging that provides clinicians with additional image enhancement for helping assess delayed cardiac wall motion.

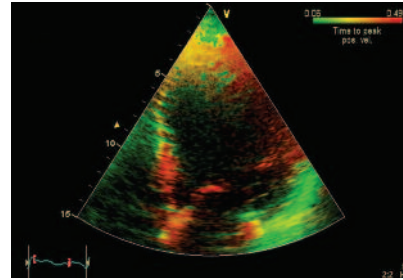
The TSI parametric image analyzes the tissue velocity signals within the image to determine the peak velocities within a specified portion of the cardiac cycle. Since these peaks will occur in relation to overall motion, delayed wall motion will produce a delayed peak velocity.

The amount of delay within the defined area of the cardiac cycle is used to assign or map a color to that location in the image. With TSI, the color represents the amount of tissue motion delay rather than the absolute value of the tissue velocity. When this technique is applied in real time across the 2D image, the variation in color provides both a qualitative and quantitative representation of wall motion delay, allowing a trained physician to readily identify and evaluate asynchronous wall motion (see Figures 6 and 7).



**Figure 6. Early Systole**

Regions reaching peak velocity in early systole are marked in green.



**Figure 7. Late Systole/Diastole**

Regions reaching peak velocity in late systole or in diastole are marked red.

Early



Late



### Synchrony

- Regions reaching peak velocity at the same time
- Regions with the same color

### Asynchrony

- Regions reaching peak velocity at different times
- Regions with different colors

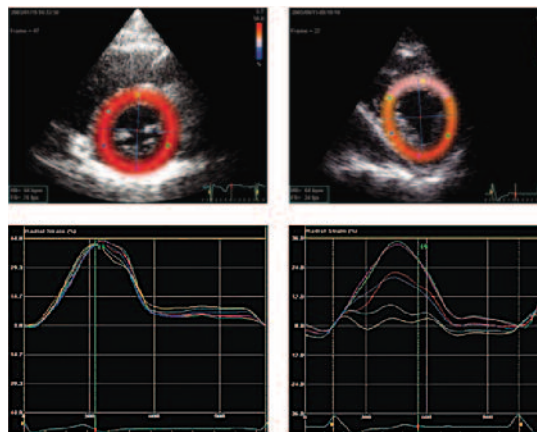


## 2D Strain

2D Strain, an expert tool, is a unique imaging mode that allows analysis of the myocardial motion throughout the entire heart cycle. Similar in concept to MRI tagging, 2D Strain analyzes motion by tracking features (natural acoustic tags) in the two-dimensional image.

2D Strain is also a natural extension of one-dimensional analysis, which is based on Doppler techniques. Similar to one-dimensional Doppler, myocardial motion is characterized in terms of tissue velocity and tissue deformation parameters, such as strain and strain rate. One of the main advantages of this technique is that it allows the Region of Interest (ROI) to be automatically tracked in the myocardium.

2D Strain is less angle dependent than Doppler-based only techniques. The 2D strain package also offers a torsion calculation tool. After processing the parasternal short-axis view at the mitral valve level (SAX-MV) and the parasternal view at the apical level (SAX-AP), the torsion button will be available.



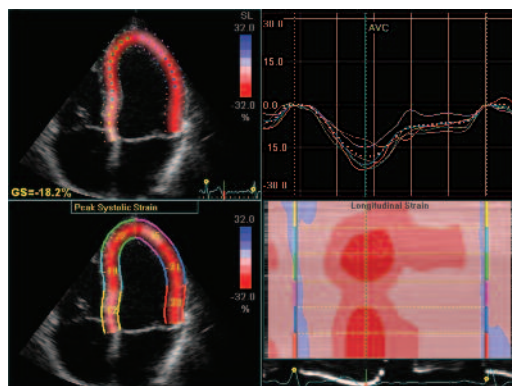
### Normal

- a) Parametric image
- b) Traces

### Pathologic

- a) Parametric image
- b) Traces

Peak radial strain values are low, especially in the anterior part.



Normal longitudinal strain displayed in quad format, and curved anatomical M-Mode.

#### References:

1. Andersen NH, Poulsen SH. Evaluation of the longitudinal contraction of the left ventricle in normal subjects by Doppler tissue tracking and strain rate. J Am Soc Echocardiogr. 2003 Jul;16(7):716-23.
2. Pan C, Hoffmann R, Kühl H, Severin E, Franke A, Hanrath P. Tissue tracking allows rapid and accurate visual evaluation of left ventricular function. Eur J Echocardiogr. 2001;2(3):197-202.
3. Sogaard P, Egeblad H, Kim WY, Jensen HK, Pedersen AK, Kristensen BO, Mortensen PT. Tissue doppler imaging predicts improved systolic performance and reversed left ventricular remodeling during long-term cardiac resynchronization therapy. J Am Coll Cardiol. 2002 Aug 21;40(4):723-30.
4. Waggoner AD, Bierig SM. Tissue Doppler imaging: a useful echocardiographic method for the cardiac sonographer to assess systolic and diastolic ventricular function. J Am Soc Echocardiogr. 2002 May;15(5):478.

For more information on GE's quantitative assessment tools, please visit us on the web at [www.gehealthcare.com](http://www.gehealthcare.com).

GE Healthcare  
9900 Innovation Drive  
Wauwatosa, WI 53226  
U.S.A.

[www.gehealthcare.com](http://www.gehealthcare.com)

©2007 General Electric Company - All rights reserved.

GE Medical Systems Ultrasound & Primary Care Diagnostics, LLC, a General Electric company, doing business as GE Healthcare.

General Electric Company reserves the right to make changes in specifications and features shown herein, or discontinue the product described at any time without notice or obligation. Contact your GE representative for the most current information.

\*GE, GE Monogram, Vivid and EchoPAC are trademarks of General Electric Company.



imagination at work